

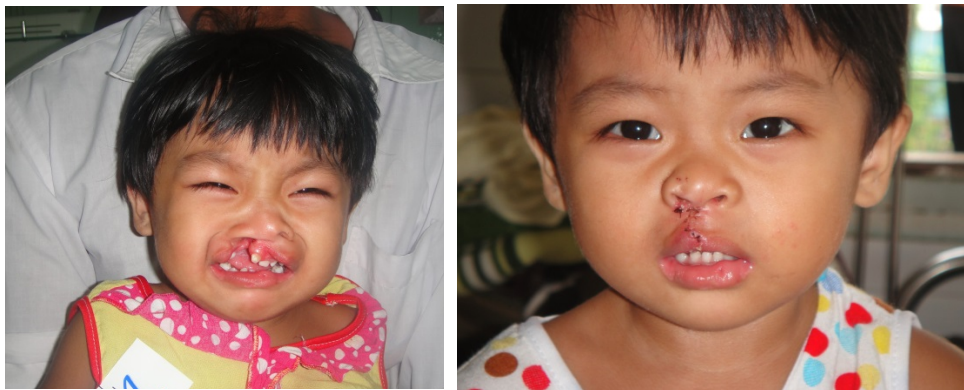Cleft Palate Missions to Ho Chi Minh City in Vietnam

Since 2005, over the past 10 years I have been very fortunate to be involved in a totally voluntary self-funded aid mission to Ho Chi Minh City in Vietnam to assist in the surgical management of children with congenital cleft palate conditions. We have visited the same hospital every year since 2005 for a period of one week, where we assess and treat cleft related patients, who come from all over Vietnam and even from Cambodia to access the members of our Monash Health Cleft Palate team. All patients are treated with no cost for their surgical or hospital care and some travel up to 700km to attend our clinic and receive treatment.

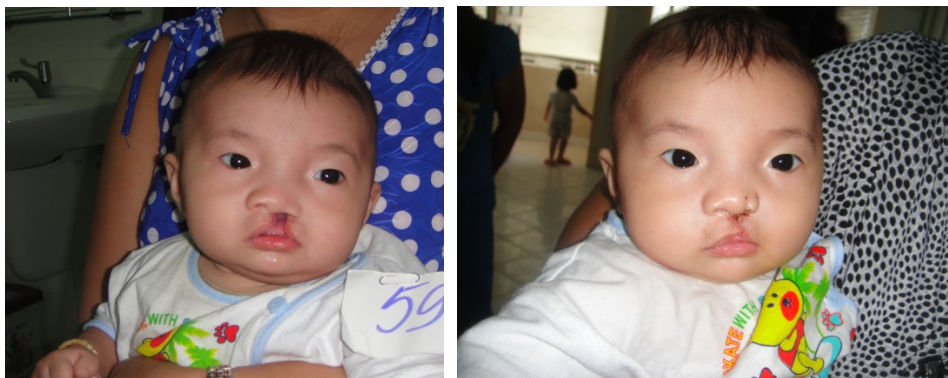The procedures are performed at the Odonto- Maxillo-Facial Hospital (BV Rang Ham Mat) in Ho Chi Minh City, where we are guests of Dr Thuy Chau, Director of Surgery. Our team consists of many members of the Monash Children's Multidisciplinary Cleft team including Plastic Surgeons, Oral Surgeons, Anaesthetists, Operating Room Nurses, Speech Pathologists and Orthodontists.

Each year we see about 100 patients, mainly children with cleft related deformities and are then able to operate on about 50 of these patients during our week long trip. We are also involved with teaching and lecturing the trainee Vietnamese surgeons and also accompanying visiting Australian trainee surgeons as well. During the 10 years of our visits to Vietnam we have established strong relationships with our hosting Vietnamese surgeons and have developed a strong affinity with Vietnam, its people and its food!

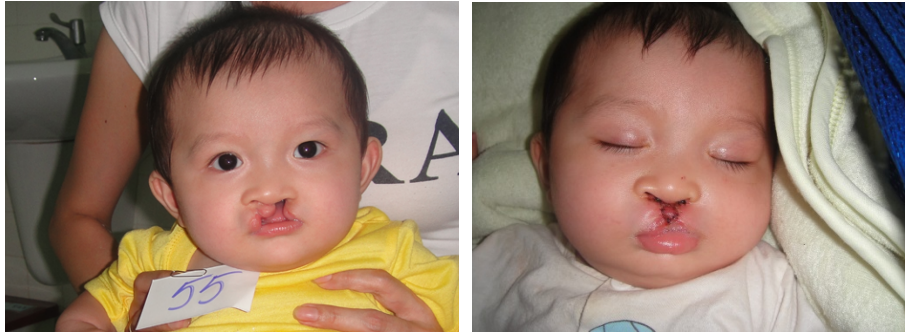I will include photos of some of the children I was fortunate enough to be able to assist on my last visit to Vietnam in 2014.



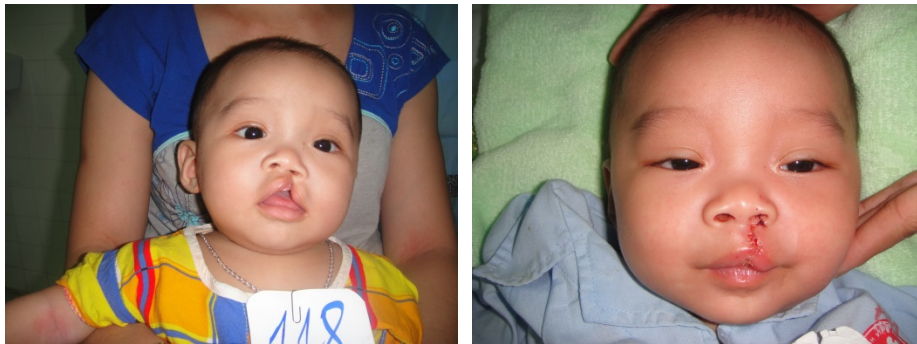9 mo girl with wide complete unilateral cleft lip and palate before and after surgery



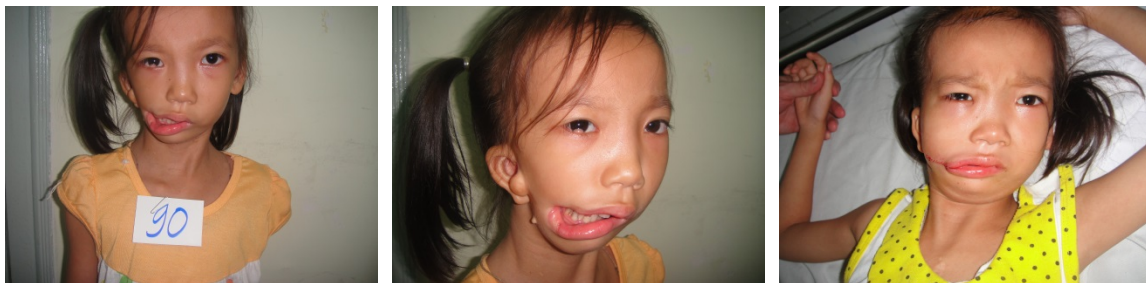
4 mo boy with complete unilateral cleft lip and palate before and after surgery



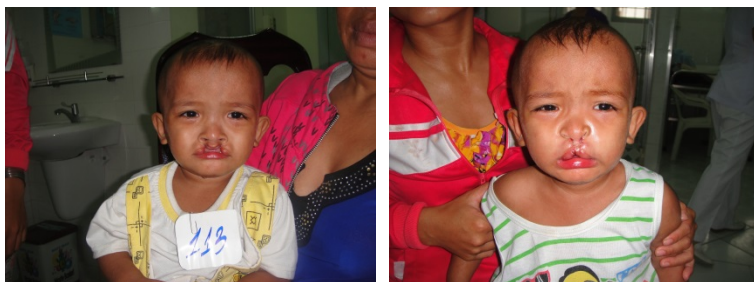6 mo boy with bilateral cleft lip and palate, incomplete on right, complete on left, before and after surgery



5 mo boy with incomplete unilateral cleft lip, before and after surgery



6 year old girl with a Tessier lateral facial cleft, before and after surgery



11 mo boy with bilateral incomplete cleft lip deformity, before and after surgery